

Case Report

Intraosseous degenerative cyst of the axis approached via transcervical extrapharyngeal avenue

Gustavo Rassier Isolan, Apio Claudio Antunes¹, Jorge Manfrim¹, Alvaro Ernani Georg¹, Frederico Falcetta¹

Department of Neurology, Porto Alegre Clinical Hospital, - Rio Grande do Sul Federal University, ¹Skull Base and Pituitary Center – Moinhos de Vento Hospital, Porto Alegre, Brazil

Corresponding author: Dr. Gustavo Rassier Isolan, Department of Neurology, Porto Alegre Clinical Hospital Rua Ramiro Barcelos, 2350, Porto Alegre, RS, Brazil. E-mail: gisolan@yahoo.com.br

Journal of Craniovertebral Junction and Spine 2012, 3:17

Abstract

Intraosseous degenerative cysts (IDC) of the cervical spine are rare. IDC within C2 have been reported in three articles only. We report a patient with neck pain due to a IDC within C2. We discuss the differential diagnosis of these lesions and the surgical approaches to reach this complex anatomical region.

Key words: Craniocervical junction, extrapharyngeal approach, intraosseous cyst

INTRODUCTION

Intraosseous degenerative cysts (IDC) of the cervical spine are rare. IDC within C2 have been reported in three articles only. We report a patient with neck pain due to an IDC within C2. We discuss the differential diagnosis of these lesions and the surgical approaches to reach this complex anatomical region.

CASE REPORT

A 43-year-old man came to our clinic with a history of significant chronic neck pain. He was referred to us due to a lesion in the axis seen on magnetic resonance imaging (MRI). The neurological examination was normal. The computed tomography showed a lytic lesion with sclerotic margins in C2. The MRI showed a lesion hypointense in T1 and hypointense in T2-signal intensity [Figure 1]. The angiography of the cervical region was normal, as

well as cintilography. Functional plain film of the cervical spine showed no instability. Based on the cervical pain and the necessity to perform a diagnosis the patient the lesion was approached. It was used an anterior transcervical extrapharyngeal approach. The anterior part of C1, C2, and C3 was exposed. A cavity within C2 was identified, and a soft material was removed. The cavity was completed with iliac bone graft. In the post-operative, the patient showed a tongue deviation to the opposite side of the approach (hypoglossal nerve alteration). Histopathological examination showed a dense fibrous tissue with no synovial layer. It was not indicated cervical instrumentation because there was no cervical instability. The patient had improvement cervical pain and is being monitoring in the last three years with cervical MRI and plain films [Figure 2].

DISCUSSION

The ganglion cysts, the synovial cysts, the arachnoid cysts, the degenerative cysts and the cysts that are located in an intervertebral disc are classified as extradural cysts and are rare.^[1] The intraosseous extradural cysts of the cervical spine are extremely rare. Being infrequently described and characterized, appearing in the literature in about 5 case reports, the differentiation of these lesions can be very demanding.

In the list of differential diagnosis some the disorders that must be considered are: Unicameral bone cyst, tumor, rheumatoid

Access this article online	
Quick Response Code:	Website: www.jcvjs.com
	DOI: 10.4103/0974-8237.116548

pannus, degenerative cyst, aneurismal bone cyst, synovial cyst, and ganglion cyst. The unicameral bone cysts frequently appear in the proximal femur or humerus, but also can be seen in the cervical vertebrae in children with 5-15 years of age. They are thought to come from a developmental defect of the epiphyseal plate. If the lesion is growing, benign and malignant tumors have to be included in the differential diagnosis, and a search to a primary site, away from the central nervous system, must be considered with exams such as bone scan. In this examination infectious process may be excluded from the differential as well. The clinical picture of atlantoaxial instability, frequently associated with rheumatoid arthritis, may form a rheumatoid pannus and this disorder has to be investigated with the proper medical and family history, physical examination and laboratory findings.^[2] The synovial cysts are characterized by having synovial fluid surrounded by a lining of synovial cells. It can be confused with a degenerative cyst, but the true synovial cyst has a communication with a synovial joint capsule near its location, or, as is the case with a synovial cyst in the cervical area, they may have a communication with adjacent facet joints. When the cysts come from degenerated spinal structures having no apparent communication with a facet they are called "degenerative intraspinal cysts."^[1] This condition is characterized by being composed of nonspecific degenerative tissue and by the absence of a synovial layer. Being included in the differential diagnosis of conditions such as rheumatoid pannus and a tumor, a degenerative cyst must be considered in the differential of an intraosseous cervical cyst, with an MRI confirming the diagnosis in almost every case.^[3] Cervical instability, in the younger population, may result from a space occupying lesion, as is the case with the aneurismal bone cysts. These lesions usually locate themselves in the posterior elements of the spine are lytic and can behave as a tumor, growing as one. The microscopic appearance of the aneurismal bone cysts is very characteristic, being described as having a spindle cell stroma the osteoclast-like giant cells and osteoid production surrounding cavernous channels.^[4,5] The aneurismal bone cyst has a solid variant that has only four case reports, been considered as extremely rare.^[5]

The gold standard exam for diagnosing synovial degenerative cysts is the MRI. This exam can differentiate, by the difference in the signal intensity and by the accuracy it has for the visualization of the spinal cord, the content of the lesions and if they are extradural or intradural respectively.^[6,7] An isointense sign in T1-weighted and a hypointense sign on T2-weighted MRI is consistent with atlantoaxial degenerative articular cysts.^[3] A hyperintense sign in T1 or T2-weighted sequences is consistent with the high protein contents of gelatinous or mucinous cyst.

The approach better suited to treat this pathology is the retropharyngeal. The advantages of this approach is related to a better and wider exposure of the rostral cervical segments of C1-C4, and a faster healing process, since there are more layers. However, the disadvantages are related to the difficulty of the technique, the quantity of visceral structures located through the approach and risk of producing a cranial nerve deficit by retraction or direct damage.

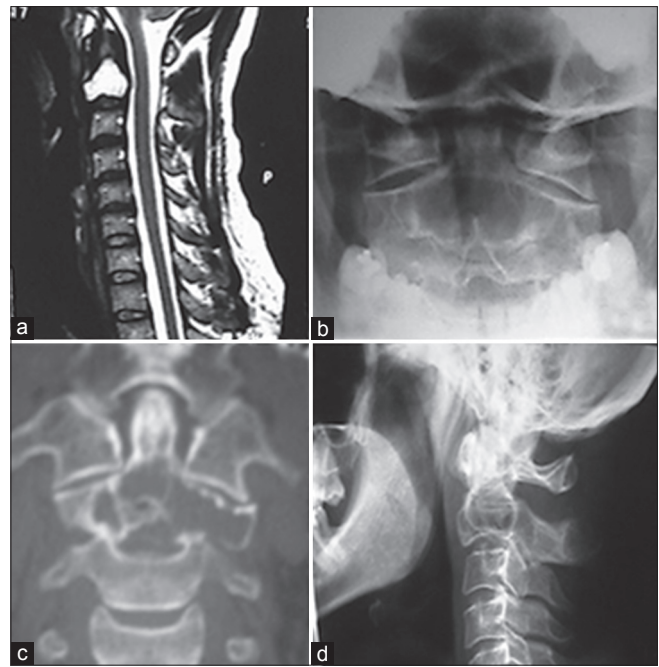


Figure 1: (a) T1 signal intensity sagittal magnetic resonance imaging showing a hyperintense lesion in C2, (b and d) plain film showing no instability, (c) computed tomography showing lytic lesion with sclerotic margins

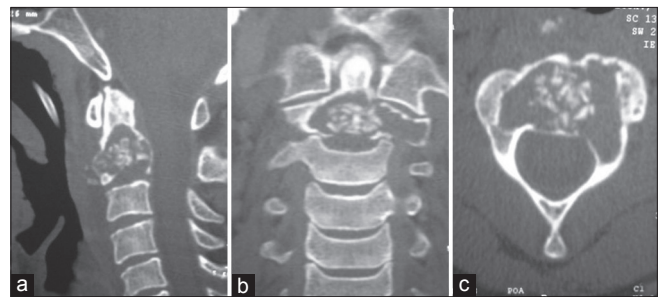


Figure 2: Post-operative. (a) Sagittal, (b) coronal and (c) axial computed tomography showing the cyst packed with crushed allograft

This approach is usually used to treat basilar impression and compression, being selected for a wider visualization of the disorder and a cleaner surgical field since it excludes an environment contaminated by bacteria that the transoral approach put up. The disorders related to Down syndrome (atlantoaxial instability and hypoplasia of the dens), Chiari I, and syringomyelia can also be treated by this approach. A post-operative spinal stabilization must be considered together with the notion that neck pain aggravated by head movements is usually a constant associated with this procedure.^[8]

CONCLUSION

The best surgical approach to treat intraosseous cervical cysts is a retropharyngeal or transoral approach. These anterior approaches are ideal so that curettage and a biopsy can be carried out without any relevant difficulty.

REFERENCES

1. McAfee PC, Bohlman HH, Riley LH Jr, Robinson RA, Southwick WO, Nachlas NE. The anterior retropharyngeal approach to the upper part of the cervical spine. *J Bone Joint Surg Am* 1987;69:1371-83.
2. Rana NA, Hancock DO, Taylor AR, Hill AG. Atlanto-axial subluxation in rheumatoid arthritis. *J Bone Joint Surg Br* 1973;55:458-70.
3. Birch BD, Khandji AG, McCormick PC. Atlantoaxial degenerative articular cysts. *J Neurosurg* 1996;85:810-6.
4. Suzuki M, Satoh T, Nishida J, Kato S, Toba T, Honda T, et al. Solid variant of aneurysmal bone cyst of the cervical spine. *Spine (Phila Pa 1976)* 2004;29:E376-81.
5. Howard DD, Bogdan C. Bone tumors. St. Louis, MO: Mosby; 1998. p. 855-912.
6. Davis R, Iliya A, Roque C, Pampati M. The advantage of magnetic resonance imaging in diagnosis of a lumbar synovial cyst. *Spine (Phila Pa 1976)* 1990;15:244-6.
7. Fritz RC, Kaiser JA, White AH, DeLong WB, Gamburd RS. Magnetic resonance imaging of a thoracic intraspinal synovial cyst. *Spine (Phila Pa 1976)* 1994;19:487-90.
8. Goel A, Shah A, Gupta SR: Craniovertebral instability due to degenerative osteoarthritis of the atlantoaxial joints: analysis of the management of 108 cases. *J Neurosurg Spine*. 2010 Jun;12:592-601

How to cite this article: Isolan GR, Antunes AC, Manfrim J, Georg AE, Falcetta F. Intraosseous degenerative cyst of the axis approached via transcervical extrapharyngeal avenue. *J Craniovert Jun Spine* 2012;3:70-2.

Source of Support: Nil, **Conflict of Interest:** None declared.

Copyright of Journal of Craniovertebral Junction & Spine is the property of Medknow Publications & Media Pvt. Ltd. and its content may not be copied or emailed to multiple sites or posted to a listserv without the copyright holder's express written permission. However, users may print, download, or email articles for individual use.